

## New horizon on community-acquired methicillin resistant *Staphylococcus aureus* (CA-MRSA) skin and soft tissue infection: nanotechnology antimicrobial spray

由社區感染的抗甲氧苯青黴素金黃葡萄球菌 (CA-MRSA) 導致的皮膚及軟組織發炎的新前景：納米科技抗菌噴霧劑

KA Wan 溫光安, MY Ng 吳美兒, YT Wong 王友德

---

The prevalence of methicillin-resistant *Staphylococcus aureus* (MRSA) in community and hospital is increasing. The development of drug resistance may be attributed to the extensive use of antibiotics. Nanotechnology antimicrobial spray (NTAS), a physical antibacterial agent, is an alternative to antibiotic treatment on wound management. We report a case of MRSA associated skin abscess using NTAS in the wound management. NTAS possesses potent, broad spectrum antibacterial effect while carrying no risk of resistance and minimal adverse effect. Moreover, NTAS facilitates home wound management, thus reducing dependency on public health resources. Further studies are indicated to explore the clinical role of NTAS in an attempt to reduce the use of antibiotics. (Hong Kong j.emerg.med. 2011;18:432-436)

抗甲氧苯青黴素金黃葡萄球菌在社區和醫院的流行率有上升趨勢。抗藥性的產生可能與廣泛使用抗生素有關。作為一種物理性的抗菌劑，納米科技抗菌噴霧劑 (NTAS) 是一種另類的傷口處理抗菌方式。我們在此報告一個使用 NTAS 治療受 MRSA 感染的皮膚膿腫病例。NTAS 擁有強力和廣譜的抗菌效力，且不會導致抗藥性及極少副作用。再者，NTAS 能促進家居傷口護理，因而減少對公共健康資源的依賴。NTAS 在減少使用抗生素方面的臨床角色值得更深入研究。

**Keywords:** Abscess, antibacterial agents, drug resistance, wound infection

**關鍵詞：**膿腫、抗菌劑、抗藥性、傷口感染

### Introduction

Since the first antibiotic, penicillin, was discovered several decades ago, antibiotics have played an important role in the treatment and prevention of diseases caused by microorganisms. Penicillin was once

a very effective antibiotic against *Staphylococcus aureus*. However, due to the extensive use of antibiotics, drug-resistant strains emerges as a result of natural selective pressure to antibiotic exposure. The first penicillinase-producing strain was found in 1944.<sup>1</sup> It was followed by methicillin-resistant *Staphylococcus aureus* (MRSA).<sup>2,3</sup> MRSA was first discovered in 1960s. Initially it was found in health care setting and involved patients with risk factors. Over the following four decades, MRSA has become a major community health problem as it spreads in the community and involves healthy individuals with no risk factor for MRSA infection. The prevalence of MRSA in both hospital and community setting is increasing.<sup>4</sup>

---

Correspondence to:

Wan Kuang An, MBBS, MRCEd, FHKAM(Emergency Medicine)  
Ruttonjee and Tang Shiu Kin Hospital, Accident and Emergency  
Department, Queen's Road East, Wan Chai, Hong Kong  
Email: wanka@ha.org.hk

Ng Mi Yi, BSc  
Wong Yau Tak, MBBS, FRCS, FHKAM(Emergency Medicine)

Newer generation antibiotics and guidelines on proper use of antibiotics have been developed to overcome the problem of drug resistance and to reduce the misuse of antibiotics. Despite these efforts, drug-resistant strains continue to develop. One example is the vancomycin-resistant *Staphylococcus aureus* (VRSA), after the use of vancomycin to combat MRSA infection. Moreover, the newer generation antibiotics may be associated with adverse effects and higher treatment cost.

Skin and soft tissue infection (SSTI) is one of the most common clinical conditions encountered in the daily practice of emergency physicians. The use of nanotechnology antimicrobial spray (NTAS) may be a breakthrough in medicine, while scientists are inventing powerful antibiotics against drug-resistant bacteria.

We have successfully managed more than ten cases of MRSA associated skin abscess by incision and drainage followed by JUC (one kind of NTAS). We here report one of these cases.

## Case

A 55-year-old gentleman suffered from a painful swelling over the scalp for five days. He had unremarkable past medical history and no history of MRSA infection. There was no history of hospitalisation, surgery or catheterisation prior to this episode of SSTI. On examination a scalp abscess measuring 3 cm in diameter was revealed. Incision and drainage was done under aseptic technique. The abscess cavity was swabbed and the specimen was sent for culture and sensitivity testing. Initially daily wound packing and saline dressing were done in General Out-patient Clinic. Three days after the incision and drainage, culture result confirmed the presence of MRSA associated with positive Panton-Valentine Leukocidine gene and type IV SCCmec typing. Community acquired MRSA (CA-MRSA) infection was confirmed. He was followed up on the same day. The wound condition was satisfactory with scanty discharge and there was no clinical evidence of wound

infection (Figure 1). He was educated on using JUC spray for wound care at home and the procedure was demonstrated once. Standardised, self-explanatory leaflets were given to enhance the patient's compliance and confidence. The patient was instructed to use JUC three times per day. Before each application, the patient cleaned the wound simply with ordinary soap or shampoo. Then the wound was dried with clean gauze. JUC was subsequently sprayed into the wound cavity. In general, one or two sprays were adequate but more sprays were necessary for larger abscess cavity initially. Spray nozzle and packing gauze were provided because of the presence of deep cavity and discharge. No other form of treatment including antibiotic was involved. Follow up on post-operative day nine and thirteen showed satisfactory wound healing, and repeat wound swab yielded no bacterial growth (Figures 2 and 3). He was satisfied with the convenience of wound care by himself, and he could manage to apply JUC on his scalp wound in front of the mirror.

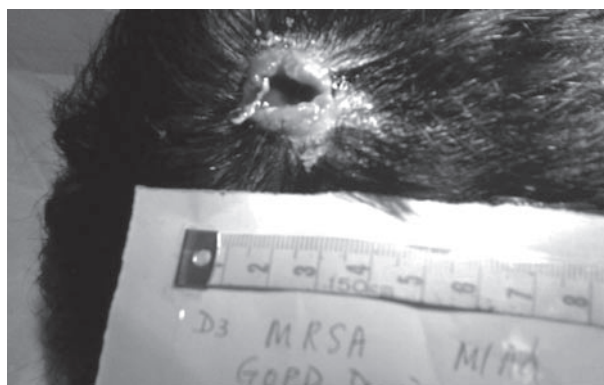

Figure 1. Post-operation day 3.

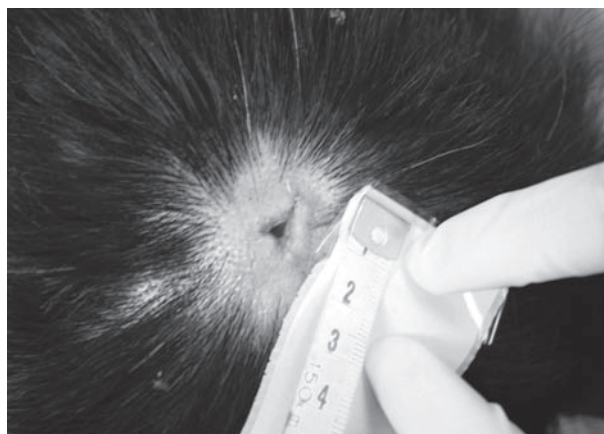


Figure 2. Post-operation day 9.

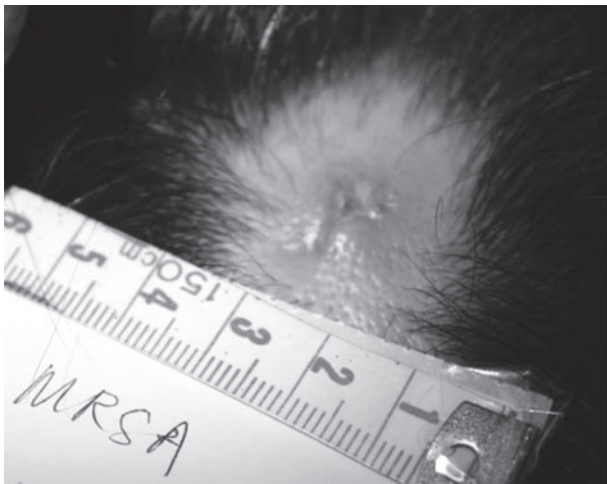


Figure 3. Post-operation day 13.

## Discussion

JUC has been introduced into our department for wound care since one year ago. It was first produced in 2002, and has been registered as a dressing product for use in general and plastic surgery by the United States Food and Drug Administration. It is made of organosilicon quaternary ammonium salt and distilled water. JUC is made through Nano-Manufacture Technology, with nano-cations on the nano-scale molecular structure produced and then prepared in water-soluble spray. JUC achieves antibacterial action on skin and wound surface by physical mechanisms and hence they can be regarded as physical antimicrobial agents.<sup>5</sup>

Bacteria are unicellular microorganisms. It has been found that these microorganisms are negatively charged. NTAS is made of nanometer cations that adsorb microorganisms by the electrostatic force between the positively charged nanometer cations and negatively charged microorganisms. This electrostatic force causes destruction of cell membrane and interferes with the mitochondrial enzyme to achieve broad-spectrum physical bactericidal effect. NTAS has been shown effective in vitro in eradicating bacteria such as *Staphylococcus aureus*, *Enterobacteriaceae* and *Pseudomonas aeruginosa*. When NTAS is sprayed and adheres onto the skin, mucosa or wound surface, it

solidifies to form an invisible antibacterial layer. The antibacterial film can kill the bacteria and prevent the bacteria from invading the skin or wound surface.<sup>5</sup>

Initially JUC was prescribed to those patients who suffered from second-degree burn. Subsequently, because of the broad-spectrum antibacterial effects, JUC has been used on infected wounds and MRSA associated skin abscess after incision and drainage. The antibacterial effect of JUC lasts for eight hours, which is longer than the ordinary antiseptics.<sup>5</sup> These patients are given JUC for wound care at home. They are educated to clean the wound with ordinary soap prior to the application of JUC. After the wound is dried properly, the JUC bottle is held about seven inches above the skin or mucous membrane, and the content is sprayed onto the surface directly. In general, one or two sprays will be adequate but more sprays may be necessary for larger abscess cavity. If the abscess cavity is deep, spray nozzles are also provided and the patients are educated on wound packing technique. They are also advised on proper personal hygiene and bathing as usual. JUC can be used two to three times every day. Follow up appointments at A&E should be arranged in order to monitor the compliance to treatment, to check the wound management technique and to assess the wound healing.

Apart from treatment of MRSA infection, NTAS may have a role in prevention of disease transmission. Colonisation of wounds by MRSA represents a significant threat in cross-infection and spread of MRSA in the community. Infection may be spread with contact of contaminated wound dressing, towel or human hands. The basic interventions for preventing spread of MRSA include hand washing, proper wound management and good hygiene. Using NTAS to eradicate MRSA on the wound and other carrier sites may be useful in controlling spread of MRSA in the community.

The Centers for Disease Control and Prevention recommends decolonisation in individuals with repeated SSTI, after infection control measures.<sup>6</sup> The current decontamination regimen involves 2% mupirocin to nasal nares twice daily for five days

together with 4% chlorhexidine bath daily.<sup>7</sup> However, a Cochrane systemic review of randomised controlled trials between 1966 and 2003 shows that there is insufficient evidence to support the use of antibiotics, either topical or systemic, to eradicate MRSA colonisation. Also there are potentially serious adverse events including the development of drug-resistant strains.<sup>8</sup> Resistance to mupirocin and chlorhexidine has been reported.<sup>6,9</sup> A prospective study has investigated the incidence of nasal carriage of MRSA on admission and the rate of MRSA colonisation during the hospital stay. Nasal carriers were given a five-day course of nasal mupirocin ointment, and daily body wash with 4% chlorhexidine and liquid soap alternatively. Eradication was achieved in nearly 99% patients after one week. However, subsequent recolonisation was common and resistant strain was found.<sup>10</sup> One newer randomised controlled trial showed the effectiveness of nasal mupirocin ointment in decolonisation of *Staphylococcus aureus* in persistent carriers, but the effect declined ninety days later.<sup>11</sup> Selective short-term use of mupirocin for specific patient group may be useful, but needs further investigation of the indications and monitoring of resistant strains.

The two commonly used preparations for hand hygiene and wound management include alcohol and chlorhexidine. However, these agents bear shortcoming in management of MRSA-colonised wound. Alcohol can denature proteins and numerous studies have proven the antimicrobial activity of alcohol.<sup>12</sup> However, alcohol may cause transient tingling discomfort when applied to wound. Chlorhexidine possesses antimicrobial activity to a wide spectrum of bacteria, fungi and virus. However, there may be concentration dependent skin irritation secondary to chlorhexidine, especially the 4% preparation.<sup>13</sup>

On the other hand, NTAS may be an ideal dressing material because it possesses antibacterial property, facilitates easy wound management and inspection, and improves quality of life as the pain associated with conventional wound dressing can be avoided. NTAS causes no serious adverse reaction to patients, and shortens the wound healing by inhibiting the growth of bacteria.<sup>14</sup> Patients are able to perform wound

dressing at home, which in turn reduces the attendance to government clinic for wound management and enhances patients' satisfaction. NTAS can be applied to area where traditional dressing may be difficult to perform e.g. axilla, vulva, groin and joint. While systemic antibiotics may create side effects and development of resistant strain, NTAS is not associated with development of resistant strain. NTAS possesses broad-spectrum antibacterial property as the electrostatic interaction between the positive charge of NTAS and negative charge of the microorganism cell membrane are the intrinsic nature and unchangeable. It is a safe, effective and convenient alternative to conventional antibiotic treatment on wound infection. Further prospective randomised controlled studies are necessary to compare the outcome between wound dressing with NTAS and conventional nurse-led wound dressing in order to further delineate the role of NTAS in wound healing and the effectiveness on wound infection.

Moreover, JUC has been shown to promote wound healing and growth of granulation tissue, to decrease wound pain, and to decrease incidence of dermatitis in the peri-colostomy skin.<sup>15,16</sup> A systematic review on the use of antimicrobial urinary catheters to prevent catheter-associated urinary tract infection showed that urinary catheter coated with antimicrobial material could prevent bacteriuria in hospitalised patients during short-term catheterisation.<sup>17</sup> Though NTAS was not included in the studies, a randomised controlled study conducted in the Mainland China has shown the role of JUC (another name of JUC) on prevention of formation of a bacterial bio-film and reduction of the incidence of catheter-associated urinary tract infection.<sup>18</sup>

In summary, NTAS may play a role in reducing the use of antibiotics in wound infection, and combating the development of resistant strains associated with injudicious use of antibiotics. Wound care with NTAS led by patients is feasible and may carry financial implications on healthcare system by reducing the demand on the service of government clinics. Further prospective clinical trials are needed to fully investigate the effectiveness and applicability of NTAS on wound management in hospital and community setting.



## References

1. Bassetti M, Nicco E, Mikulska M. Why is community-associated MRSA spreading across the world and how will it change clinical practice? *Int J Antimicrob Agents* 2009;34 Suppl 1:S15-9.
2. Frank AL, Marcinak JF, Mangat PD, Schreckenberger PC. Increase in community-acquired methicillin-resistant *Staphylococcus aureus* in children. *Clin Infect Dis* 1999;29(4):935-6.
3. Gorak EJ, Yamada SM, Brown JD. Community-acquired methicillin-resistant *Staphylococcus aureus* in hospitalized adults and children without known risk factors. *Clin Infect Dis* 1999;29(4):797-800.
4. Chambers HF. The changing epidemiology of *Staphylococcus aureus*? *Emerg Infect Dis* 2001;7(2):178-82.
5. Ministry of Health, P.R. China. The project of generalizing one hundred achievements during ten years: the plan of the patent technology of physical antimicrobial film on skin solving the problems of local infection and hospital-acquired infection; 2007.
6. Gorwitz RJ, Jernigan DB, Powers JH, Jernigan JA. Strategies for Clinical Management of MRSA in the Community: Summary of an experts' meeting convened by the Centers for Disease Control and Prevention. 2006. Available from: <http://www.cdc.gov/mrsa/pdf/MRSA-Strategies-ExpMtgSummary-2006.pdf>.
7. Guilbeau JR, Fordham PN. Evidence-based Management and Treatment of Outpatient Community-Associated MRSA. *J Nurse Pract* 2010;6(2):140-5.
8. Loeb MB, Main C, Walker-Dilks C, Eady A. Antimicrobial drugs for treating methicillin-resistant *Staphylococcus aureus* colonization. *Cochrane Database of Systematic Reviews*, 2003;(4):Art. No.: CD003340 [updated 2003 Aug 24; published online 2008 Oct 8]. Available from: <http://onlinelibrary.wiley.com/doi/10.1002/14651858.CD003340/abstract>.
9. Thomas L, Maillard JY, Lambert RJ, Russell AD. Development of resistance to chlorhexidine diacetate in *Pseudomonas aeruginosa* and the effect of a "residual" concentration. *J Hosp Infect* 2000;46(4):297-303.
10. Dupeyron C, Campillo B, Bordes M, Faubert E, Richardet JP, Mangeney N. A clinical trial of mupirocin in the eradication of methicillin-resistant *Staphylococcus aureus* nasal carriage in a digestive disease unit. *J Hosp Infect* 2002;52(4):281-7.
11. Mody L, Kauffman CA, McNeil SA, Galecki AT, Bradley SF. Mupirocin-based decolonization of *Staphylococcus aureus* carriers in residents of 2 long-term care facilities: a randomized, double-blind, placebo-controlled trial. *Clin Infect Dis* 2003; 37(11):1467-74.
12. Larson EL; 1992, 1993 and 1994 APIC Guidelines Committee. APIC Guidelines for handwashing and hand antisepsis in health care settings. *Am J Infect Control* 1995;23(4):251-69.
13. Stingeni L, Lapomarda V, Lisi P. Occupational hand dermatitis in hospital environments. *Contact Dermatitis* 1995;33(3):172-6.
14. Zeng Y, Deng R, Yeung BHS, Loo WTY, Cheung MNB, Chen JP, et al. Application of an antibacterial dressing spray in the prevention of post-operative infection in oral cancer patients: A phase 1 clinical trial. *Afr J Biotechnol* 2008;7(21):3827-31.
15. Shen MF, Li Z. [Utilization of JUC in management of open wounds]. *Herald of Medicine* 2006;25(2):138-9. Chinese.
16. Shen RR, Sun HF, Mao YF. Effect of JIU-YOU-SHEN to pericostomy skin. *Mod Nurs* 2006;12(22):2096.
17. Johnson JR, Kuskowski MA, Wilt TJ. Systematic Review: antimicrobial urinary catheters to prevent catheter-associated urinary tract infection in hospitalized patients. *Ann Intern Med* 2006;144(2):116-26.
18. Wu L, Dai YT, Wang LM, Cheng B, Sun ZY. Study on prevention of catheter associated urinary tract infection by using JUS long-acting antibacterial material. *Zhonghua Nan Ke Xue* 2005;11(8):581-3.