

Evaluation of Wound Healing Efficacy of an Antimicrobial Spray Dressing at Skin Donor Sites

Lien-Guo Dai, MD, PhD¹; Keng-Yen Fu, PhD²; Pai-Shan Hsieh, MS²; Yu-Min Hung, MS³; Yi-Wen Wang^{4,5}, PhD; Li-Chuan Hsia², RN; Shun-Cheng Chang, MD, PhD²; Chih-Hsin Wang, MD²; Shou-Cheng Teng, MD²; Shyi-Gen Chen, MD²; Tim-Mo Chen, MD²; Niann-Tzyy Dai, MD, PhD²

Wounds 2015;27(8):224-228

From the ¹Department of Orthopedics, Shuang Ho Hospital, Taipei Medical University, Taipei, Taiwan, ROC; ²Division of Plastic and Reconstructive Surgery, Department of Surgery, Tri-Service General Hospital, National Defense Medical Center, Taipei, Taiwan, ROC; ³Institute of Polymer Science and Engineering, National Taiwan University, Taipei, Taiwan, ROC; ⁴Department of Biology and Anatomy, Tri-Service General Hospital, National Defense Medical Center, Taipei, Taiwan, ROC; ⁵Burn Center, Tri-Service General Hospital, Taipei, Taiwan, ROC

Address correspondence to:

Niann-Tzyy Dai, MD, PhD

Division of Plastic and Reconstructive Surgery, Department of Surgery
Tri-Service General Hospital, National Defense Medical Center, Taipei, ROC
No. 325, Section 2, Cheng-Kung Road, Nei-Hu District
Taipei 114, Taiwan, ROC
niantzyy_dai@hotmail.com

Disclosure: Financial support for this work was provided by the Ministry of National Defense, ROC (C-05-01, MAB101-45, MAB102-5, 103-M015), National Defense Medical Center and Tri-Service General Hospital, ROC (TSGH-C100-013-S02, TSGH-C101-008-013-S02, TSGH-C102-006-008-013-S02, TSGH-C103-139). Additional financial support was provided by Teh-Tzer Study Group for Human Medical Research Foundation, Taiwan, Republic of China.

NMS Technologies Co Ltd, Nanjing, China, and ConvaTec, Bridgewater, NJ, provided products for the purposes of this study.

Abstract: *Introduction.* Autologous skin transplantation is a common treatment for patients with full-thickness burns. Postoperative wound care is essential for skin graft donor and recipient sites, but traditional wound dressings such as cotton and gauze do not form an effective barrier to bacteria, and patients can feel uncomfortable when replacing dressings. *Materials and Methods.* The goal of this study was to evaluate the use of an antimicrobial spray dressing (JUC Spray Dressing, NMS Technologies Co Ltd, Nanjing, China), with respect to its antimicrobial efficiency and the degree of pain experienced by patients. *Results.* The authors found the antimicrobial spray can reduce pain during the recovery period, while providing equivalent antibacterial protection to the control treatment (AQUACEL Hydrofiber Wound Dressing, ConvaTec, Bridgewater, NJ) based on skin culture tests. The spray did not adversely affect the wound site recovery. No significant side effects were present during the treatment period. *Conclusion.* This antimicrobial spray could potentially be used in wound dressing applications.

Key words: full-thickness burn, antimicrobial spray, wound dressing, antimicrobial efficiency, pain

The process of wound recovery is continuous, complex, dynamic, and sophisticated, and is affected by both internal factors and the external environment. Internally, extracellular matrix (ECM) deposition and reepithelialization play an important role because they produce a barrier to resist microbial invasion. With respect to external factors, the ability to control infection determines whether the wound site will continue to deteriorate. Tissue can often no longer regenerate after a deep injury; therefore, the wound area requires a dressing to assist recovery.¹ A temporary dressing is a useful and commonly used treatment to provide a suitable environment for wound healing.

Burns are painful and severe injuries that have a radical impact on the human body. Grafting and excision have been the backbone of burn

treatment for 100 years.² Burn wounds often require a skin autograft to provide a suitable environment for healing. However, procedural pain from repeated treatment such as skin debridement and prolonged dressing changes can be severe.^{3,4} Conventional wound dressings such as plaster, gauze, and advanced wound dressings could protect the wound, although the application and removal of these dressing materials may cause pain.⁵

An antimicrobial spray dressing (JUC Spray, NMS Technologies Co. Ltd, Nanjing, China) includes quaternary ammonium salts that have been widely used as antimicrobial agents. Their antimicrobial activity may be related to the negatively charged cell surfaces of bacteria that attract the positively charged salts and allow them to disrupt the cell membrane.⁶ Therefore, once the antimicrobial spray is applied to the skin surface, it forms a positive charge film to kill and isolate bacteria. The antimicrobial properties of these salts could be altered to fit different applications by changing their functional groups.^{7,8}

Some areas of the body are difficult to protect from microbial infection using traditional wound dressings, and the broad-spectrum antimicrobial spray could be a useful alternative in these cases. Unlike chemical-based treatment, antimicrobial barriers will not produce bacterial resistance. This dressing spray was used in a study to control oral infection after an operation in the oral cavity, and was shown to significantly improve healing in all patients without any obvious side effects.⁹ In the current study, the authors investigated the efficacy of the antimicrobial spray in preventing infection at a skin donor site.

Materials and Methods

The antimicrobial spray was provided by NMS Technologies Co Ltd, Nanjing, China for the purposes of this study, and polyurethane film (Tegaderm, 3M, St. Paul, MN) was purchased for use as a cover film. An advanced wound dressing (AQUACEL Hydrofiber Wound Dressing, ConvaTec, Bridgewater, NJ) was provided by the company for use as a control treatment.

Clinical case criteria. One hundred patients undergoing skin autografting were recruited for this study from the Tri-Service General Hospital, National Defense Medical Center, Taiwan, Republic of China, between July 30, 2012 and June 30, 2013. A skin graft donor site of both thigh areas measuring less than 10% total body surface area was tested, and the wound was

KEYPOINTS

- One hundred patients undergoing skin autografting were recruited for this study from the Tri-Service General Hospital, National Defense Medical Center, Taiwan, Republic of China, between July 30, 2012 and June 30, 2013.
- A skin graft donor site of both thigh areas measuring less than 10% total body surface area was tested, and the wound was treated within 24 hours.
- Patients were randomly divided into an antimicrobial spray group and a control-treated group.

treated within 24 hours. Patients were randomly divided into an antimicrobial spray group and a control-treated group. The patients consisted of 35 men and 23 women between 34 and 50 years old. This study protocol was registered and approved by the National Defense Medical Center (TSGHIRB No.: 1-101-03-001). The inclusion criteria were patients with burns undergoing autologous skin surgery who had donor site exudate; no obvious signs of infection (ie, redness or fever); and were able to self-assess. The exclusion criteria were significant donor site infection or systemic manifestations of infection, a dry donor site or one with very little exudate; existing skin diseases; severe cardiopulmonary dysfunction; and any other reason (eg, severe diseases such as liver and kidney dysfunction that may have seriously interfered with wound repair) determined by the study investigator.

Treatment and evaluation standard. After surgery, the donor sites underwent conventional iodine disinfection, wound tissue was taken for culture, and the color of the wound site was recorded. For the experimental group, the antimicrobial spray was applied uniformly to the wound site, where it solidified immediately to produce an invisible protective layer. This layer contains quaternary ammonium salts that have antibacterial properties. The wound site was protected with polyurethane film that was replaced every 2-3 days as required. Patients in the control group were subject to routine disinfection using only hydrocolloid dressings. Pain was measured using the Visual Analogue Scale (VAS), where 0 indicated no pain and 10 indicated extreme pain. Samples were taken from the donor site at 0, 4, 8, and 12 days for evaluation of infection and morphology, and the estimated time needed for healing, based on the clinician's assessment, was recorded.

Tissue culture at wound sites. A cotton swab was used to collect bacteria from the wound area, and then

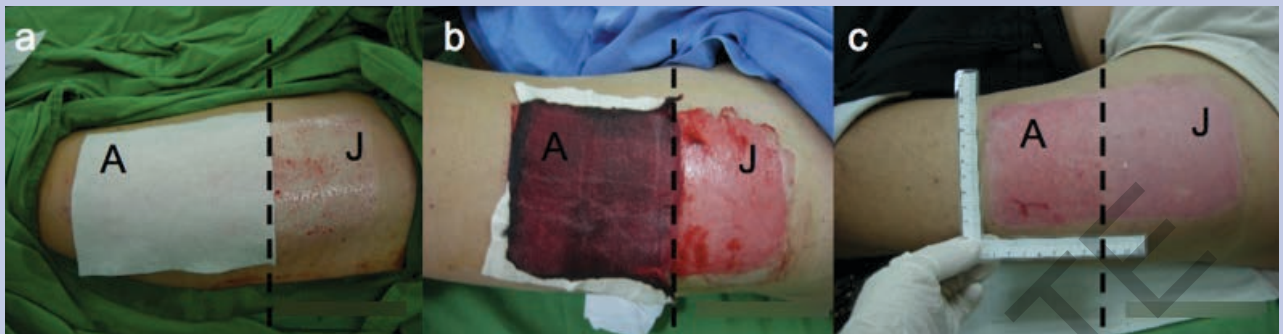


Figure 1. The photograph of wound closure at different time points: (a) initial treatment; (b) 3 days of treatment; and (c) 15 days after surgery and treatment with either the control dressing (A) or the antimicrobial spray (J).

KEYPOINTS

- The wound healing times when in the antimicrobial spray group were 16.74 ± 4.76 days, and 16.13 ± 4.84 days in the control group (Table 1), but the difference was not statistically significant.
- The number of cultures positive for bacteria increased to 0.18% in the control group and 0.17% in the antimicrobial spray group after 7 to 8 days of treatment (Table 1); however, none of these differences were statistically significant.
- The Visual Analog Scale score for pain exponentially decreased during treatment for both groups; however, the pain scores of the antimicrobial spray group at any of the time intervals were less than those of the control group (Table 1).

delivered to the Division of Clinical Pathology, Tri-Service General Hospital for analysis with a wound and pus culture. Microbes detected in the tissue cultures included diptheroids, *Staphylococcus epidermidis*, and *Proionbacterium acnes*. If no colonies, or very few colonies, were present on the culture plate, the result was recorded as negative; otherwise, the result was recorded as positive.

Statistical analysis. Except for tissue culture results expressed as a percentage of the population, results are presented as the mean \pm standard deviation. Statistical differences were analyzed using Student's *t* test, and differences were considered to be significant for *P* values < 0.05 .

Results

Wound healing time and morphology. A visual representation of the wound sites is presented in Figure 1. Compared with the control dressing, the antimicro-

bial spray allowed a clear view of the wound site at the beginning of treatment (Figure 1a). Three days later, the control dressing had absorbed a great quantity of exudate, but because the antimicrobial spray forms only a thin film, the exudate could evaporate. In addition, the wound was easier to clean, so the wound surface was drier than when using the control (Figure 1b). After 15 days, the wound pictured had almost healed, and the wound sites of both groups showed no significant differences (Figure 1c).

The wound healing times in the antimicrobial spray group were 16.74 ± 4.76 days, and 16.13 ± 4.84 days in the control group (Table 1), but the difference was not statistically significant. This indicates the protective film from the antimicrobial spray did not adversely affect the wound site recovery. None of the patients showed any side effects during the study period.

Wound culture. Before wound treatment, culture tests showed no obvious bacteria from the donor area in either group. After 3 days of treatment, 0.03% of the antimicrobial spray group, but none in the control group, had a positive culture test. The number of cultures positive for bacteria increased to 0.18% in the control group and 0.17% in the antimicrobial spray group after 7 to 8 days of treatment (Table 1); however, none of these differences were statistically significant.

Visual analog score. The VAS score exponentially decreased during treatment for both groups; however, the pain scores of the antimicrobial spray group at any of the time intervals were less than those of the control group (Table 1). No patient in either treatment arm reported a VAS score greater than 4, and before treatment and 3 days postoperation there were statistical differences ($P < 0.05$) between the antimicrobial spray and control groups with respect to the VAS score.

Table 1. The results of treatment with a control dressing or an antimicrobial spray after surgery.

Parameters	Measurement time point	Antimicrobial spray dressing (n = 30)	Control dressing (n = 28)	P
Positive wound culture (Percentage of population)	Preoperation	0 (0.00%)	0 (0.00%)	
	3 days postoperation	1 (0.03%)	0 (0.00%)	
	7~8 days postoperation	5 (0.17%)	5 (0.18%)	
Visual analog score (0-10)	Preoperation	2.87 ± 0.22	3.71 ± 0.27	0.004497
	7~8 days postoperation	1.87 ± 0.20	3.00 ± 0.29	0.001533
	11~12 days postoperation	1.43 ± 0.19	2.11 ± 0.33	0.033734
	15~16 days postoperation	0.67 ± 0.17	1.21 ± 0.28	0.087392
Wound healing time (day)	Complete wound healing	16.43 ± 0.78	16.14 ± 0.91	0.752814

Discussion

Burn treatment and healing are complex processes. Burn wounds are prone to bacterial infections that may delay healing. Thus, good autograft wound recovery is essential to prevent fluid and nutrient loss and promote healing.¹⁰

The main ingredients of the antimicrobial spray used in this study are water and quaternary ammonium salts, which act as cation particles. As an aerosol, the antimicrobial spray can uniformly cover wound sites and form a thin antimicrobial layer. This layer provides a barrier between the wound and the external environment, thus preventing disease transmission. Unlike conventional dressings, this method can be used for any part of the body and can reduce the risk of wound-dressing detachment, which results from physical activity. Microorganisms such as bacteria carry a net negative charge. When bacteria are close to wound sites, the electrostatic force leads the cation particles to absorb negatively charged bacteria. This disrupts bacterial cell membranes and leads to a loss of structure and cellular activity.¹¹ In this clinical study, the spray showed efficient antimicrobial activity. There were a few infections after treatment with the antimicrobial spray, but this may have been caused by sweat from physical activity that could have caused a loss of the protective film. To enable widespread use of the antimicrobial spray, the timing of changing wound dressings that have been placed over skin treated with the antimicrobial spray should be researched and discussed to test for limits of adherence.

Autograft is a common and useful way to treat burn

wounds, but recovery depends heavily on postoperative care; for most patients, this is a huge challenge. Pruritus and pain at the wound site is a serious problem, especially for burn patients with comorbidities, and represents both a psychological and physiological burden during treatment. Pain control is essential to improve the patient's quality of life. Currently, long-term pain control using medications like methadone or morphine reduces background pain and promotes recovery,¹² but the associated side effects such as respiratory depression, sedation, nausea, or constipation could prove problematic. Antimicrobial spray can reduce pain at the donor site by forming a physical barrier and can reduce pain significantly ($P < 0.05$), especially in the initial recovery period. The authors found that, even when the donor site had almost healed, the VAS score of the antimicrobial spray group was lower than that of the control group, suggesting antimicrobial spray is useful for reducing pain throughout recovery. In addition, no significant side effects were observed during the treatment period, indicating that the antimicrobial spray can be used as a treatment tool to improve the quality of life of burn patients.

Conclusion

The objective of this study was to determine whether an antimicrobial spray is superior to conventional wound dressings. Burns are an accidental injury that can result in long-term pain during recovery. The antimicrobial spray is an ideal wound dressing, because it could effectively reduce pain while being suitable for wounds in areas difficult to fit with a conventional

dressing. The wound healing times are comparable between the control dressing and the antimicrobial spray. In addition, none of the patients had any side effects after surgery. Therefore, antimicrobial spray may be useful in a variety of postoperative applications.

References

1. Gu J, Liu N, Yang X, Feng Z, Qi F. Adipose-derived stem cells seeded on PLCL/P123 electrospun nanofibrous scaffold enhance wound healing. *Biomed Mater.* 2014;9(3):035012. doi:10.1088/1748-6041/9/3/035012.
2. Ghosh SJ, Kumar K, Gilbert PM. Opsite spray: its use for fixation of meshed skin grafts. Simple and low tech. *Burns.* 1997;23 (7-8):601-603.
3. Jellish WS, Gamelli RL, Furry PA, McGill VL, Fluder EM. Effect of topical local anesthetic application to skin harvest sites for pain management in burn patients undergoing skin-grafting procedures. *Ann Surg.* 1999;229(1):115-120.
4. Summer GJ, Puntillo KA, Misaskowski C, Green PG, Levine JD. Burn injury pain: the continuing challenge. *J Pain.* 2007;8(7):533-548.
5. Laila L, Febriyenti F, Salhimi SM, Baie S. Wound healing effect of Haruan (*Channa striatus*) spray. *Int Wound J.* 2011;8(5):484-491.
6. Zhou W, Ma KQ, Tang LH, Li F, Huang L, Chen JH. Synthesis and properties of a polymerizable quaternary ammonium salt. *J Appl Polym Sci.* 2014;131(21):41002. doi: 10.1002/app.41002.
7. Tischer M, Pradel G, Ohlsen K, Holzgrabe U. Quaternary ammonium salts and their antimicrobial potential: targets or nonspecific interactions? *ChemMedChem.* 2012;7(1):22-31.
8. Muñoz-Bonilla A, Fernández-García M. Polymeric materials with antimicrobial activity. *Prog Polym Sci.* 2012;37(2):281-339.
9. Zeng Y, Deng R, Yeung BHS, et al. Application of an antibacterial dressing spray in the prevention of postoperative infection in oral cancer patients: A phase I clinical trial. *Afr J Biotechnol.* 2008;7(21):3827-3831.
10. Wood FM, Kolybaba ML, Allen P. The use of cultured epithelial autograft in the treatment of major burn wounds: eleven years of clinical experience. *Burns.* 2006;32(5):538-544.
11. Wan KA, Ng MY, Wong YT. New horizon on community-acquired methicillin resistant *Staphylococcus aureus* (CA-MRSA) skin and soft tissue infection: nanotechnology antimicrobial spray. *Hong Kong J Emerg Med.* 2011;18(6):432-436.
12. Sen S, Palmieri T, Greenhalgh D. Review of burn research for the year 2013. *J Burn Care Res.* 2014;35(5):362-368.